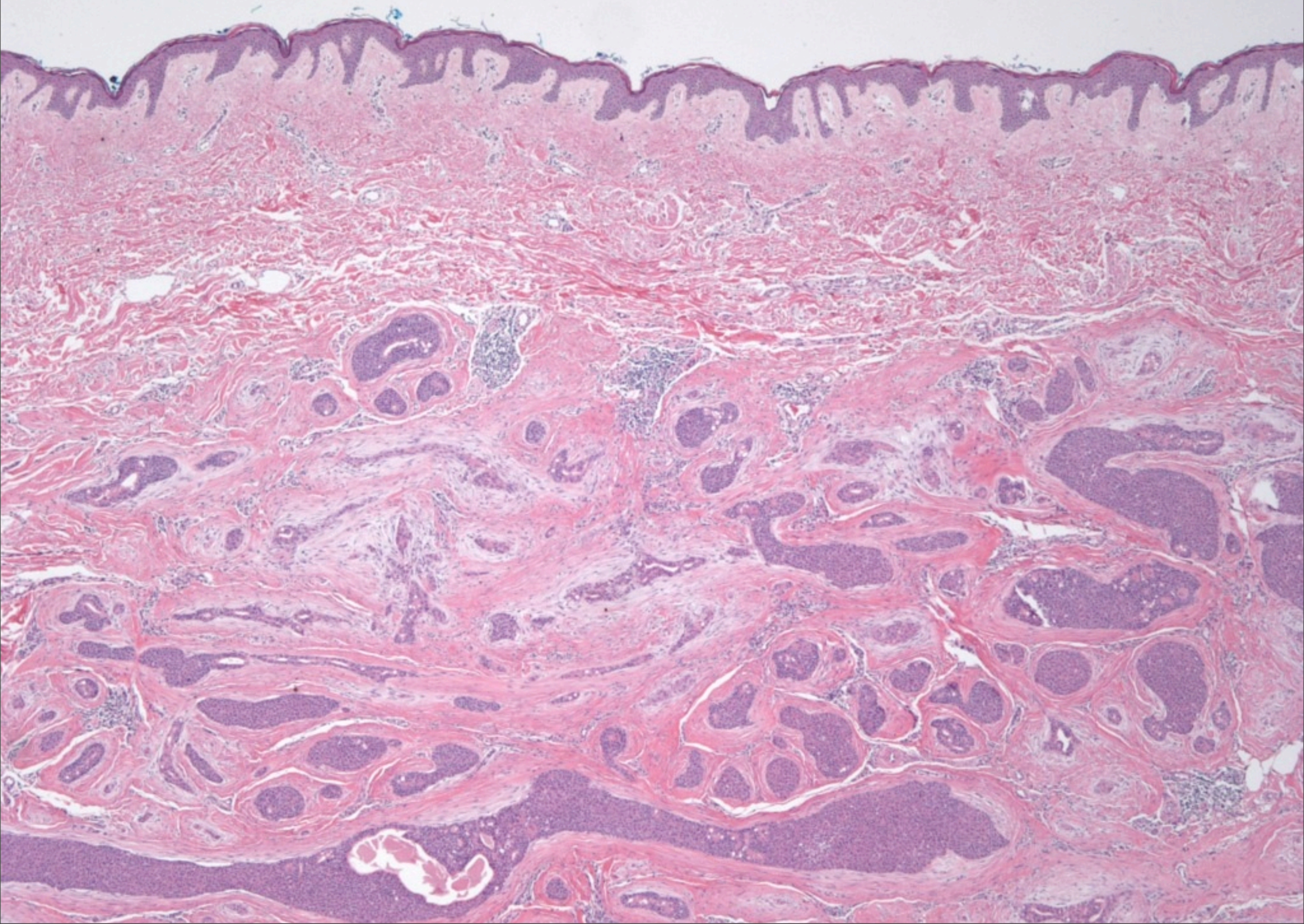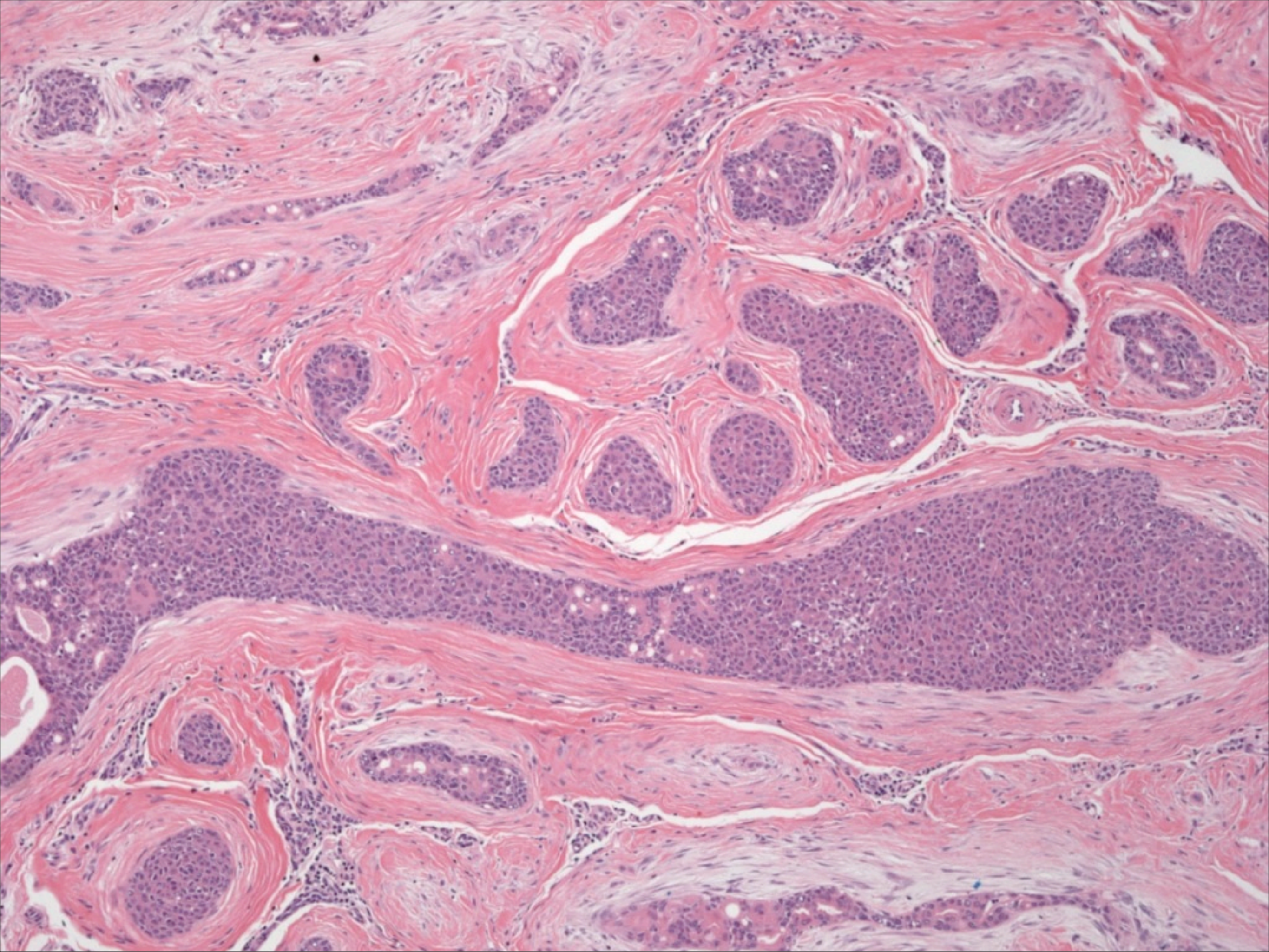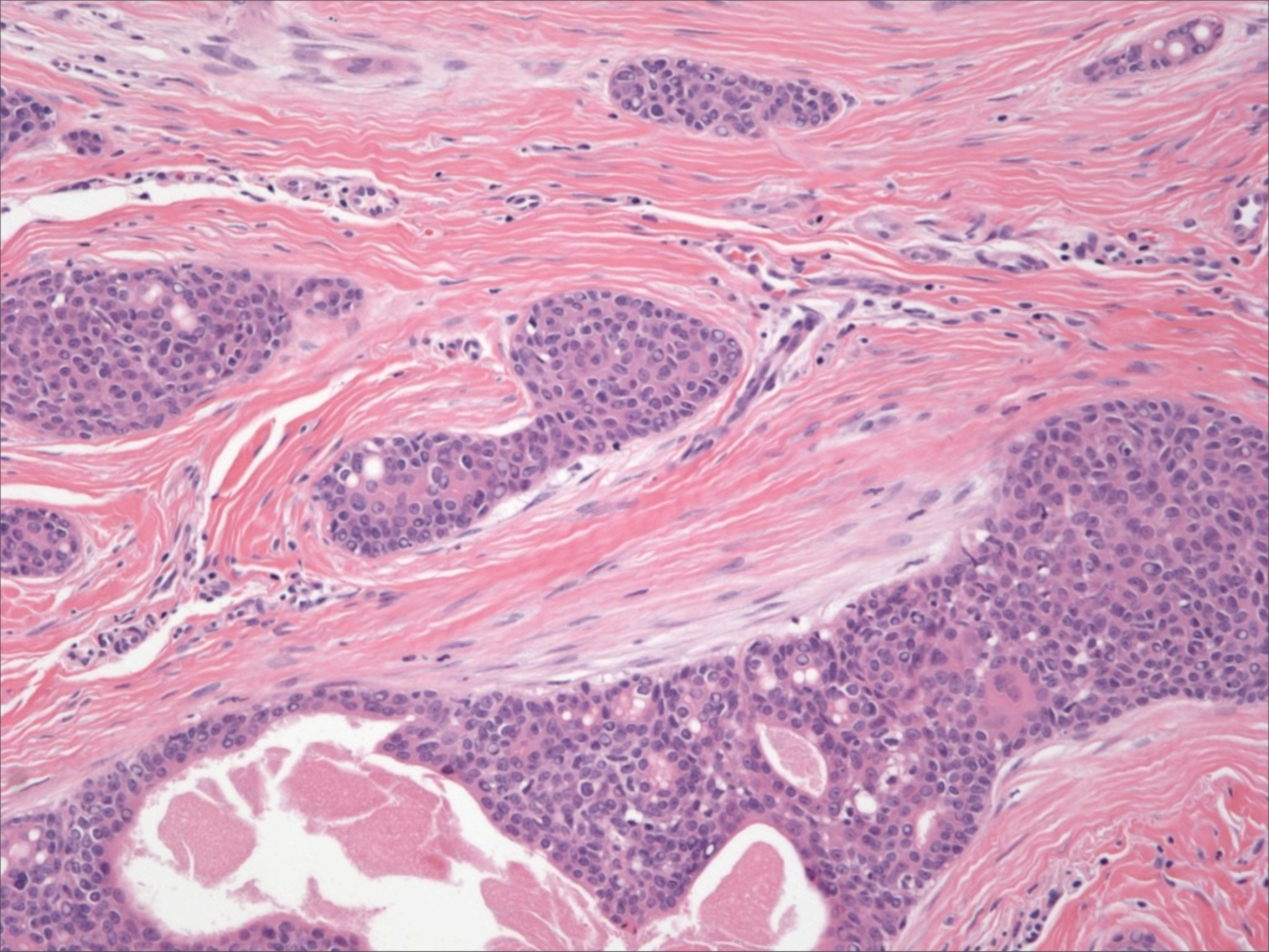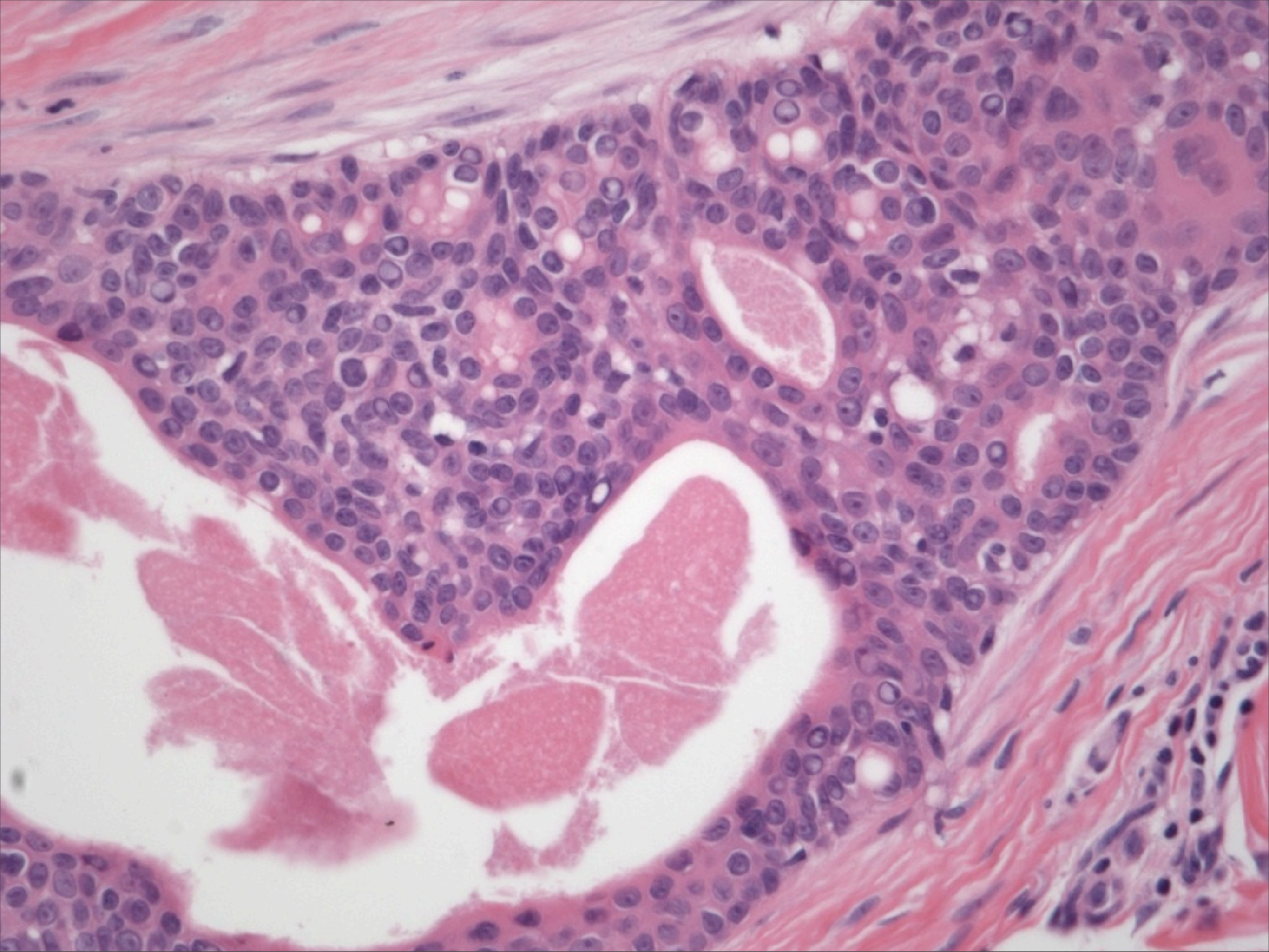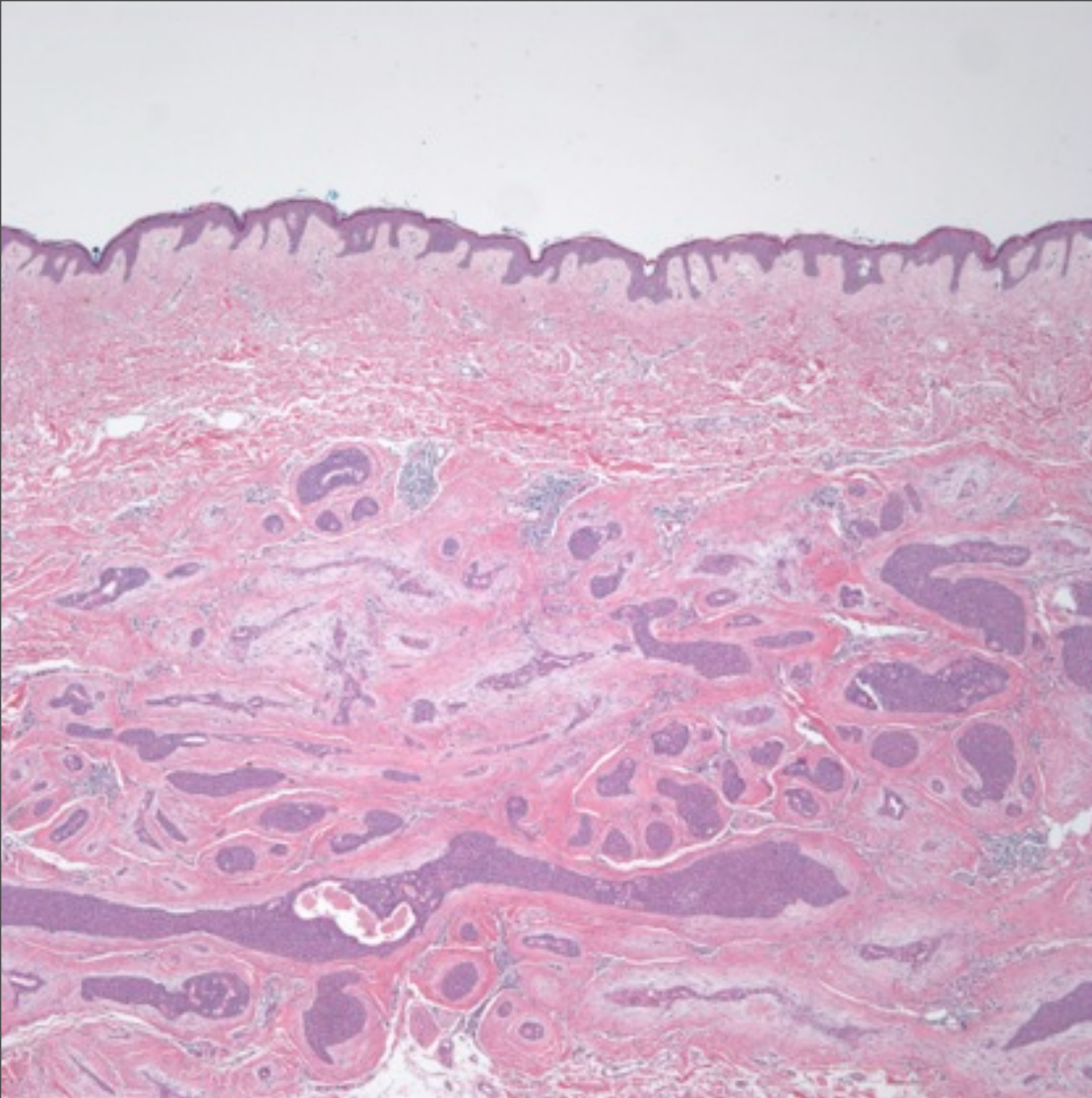
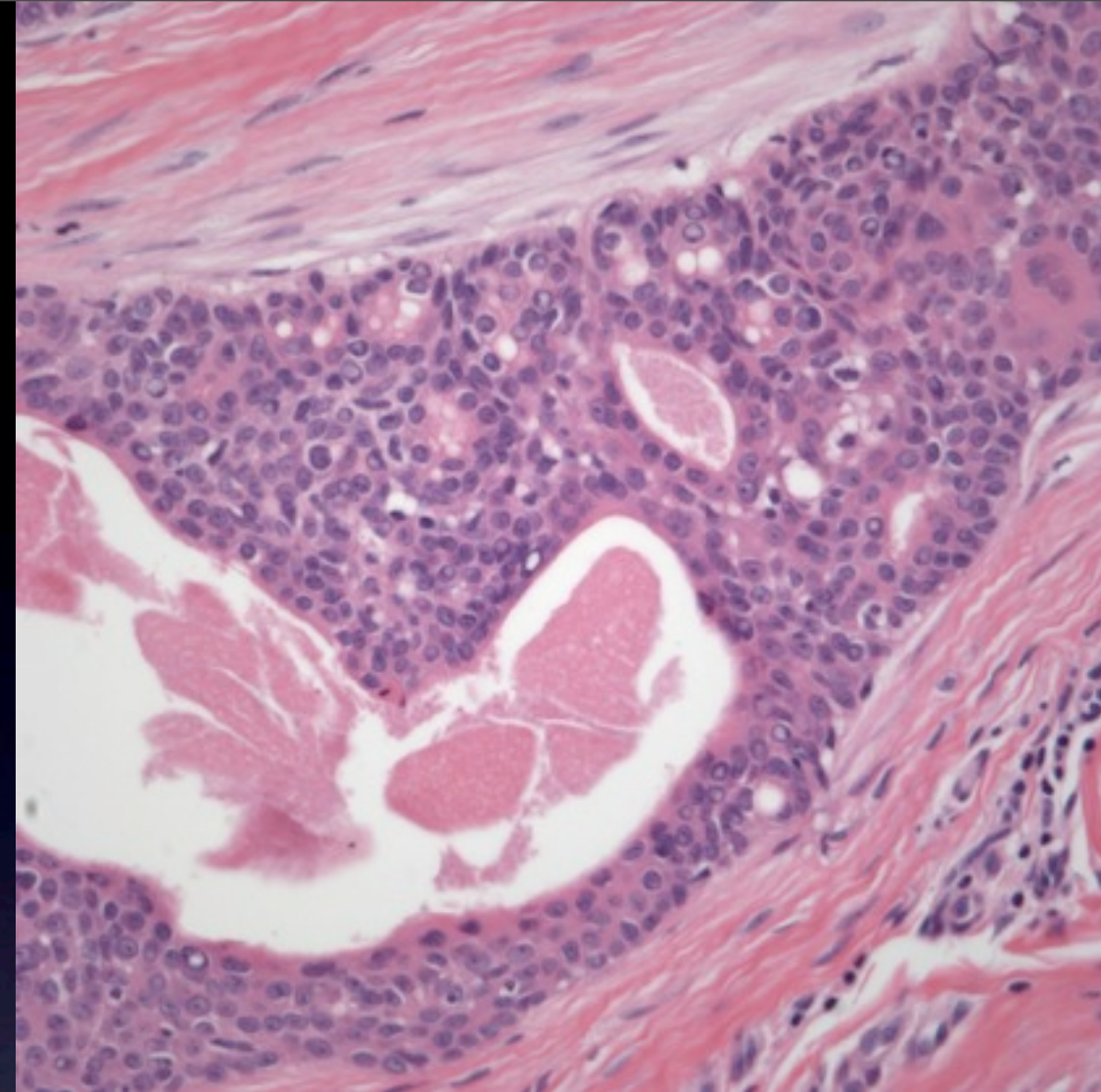


Porocarcinoma



Infiltrative dermal
neoplasm



Squamous epithelial cells with
ductal differentiation

Variable cytologic atypia